

Technical Note

Arthroscopic Knotless Rotator Cuff Repair With Decellularized Dermal Allograft Augmentation: The “Canopy” Technique

Alan M. Hirahara, M.D., F.R.C.S.C., Wyatt J. Andersen, M.S.H.S., A.T.C., and Tom Dooney

Abstract: Repairability and clinical outcomes of full-thickness rotator cuff tears rely on tendon mobility, tissue quality, and subsequent tension on a repair. While repair of rotator cuff tears tend to yield excellent clinical results, poor tissue quality has been an important factor that has hampered successful outcomes. This Technical Note describes a double-row rotator cuff repair using a SpeedBridge configuration with dermal allograft “canopy” augmentation to bolster the repairable but thinned rotator cuff tissue. This technique employs a unique graft fixation strategy to simplify the procedure. This approach could provide surgeons with a great option when faced with mobile but thinned rotator cuff tissue.

Determination of the appropriate surgical technique when faced with a full-thickness rotator cuff tear is dependent on several factors, including tissue mobility, tissue quality, and tension on the subsequently repaired tissue. The ability of the tendon to mobilize to the insertion site at the greater tuberosity is paramount as an immobile tear may warrant more elaborate procedures like a superior capsular reconstruction (SCR).¹⁻⁴ For the mobile tendon, the quality of and tension on the tissue also must be amenable to a repair. In the setting of a tear that can be reduced to the greater tuberosity, but has poor tissue quality, a repair may require additional reinforcement through graft augmentation to help prevent tear-through of the tissue and subsequent tissue failure. This Technical

Note describes a technique for the arthroscopic repair of rotator cuff tears using a knotless SpeedBridge configuration and dermal allograft “Canopy” augmentation. A unique graft fixation technique is employed to simplify graft attachment during the procedure.

Surgical Technique (With Video Illustration)

Patient Setup and Preparation

The patient is placed in a beach chair position and a diagnostic arthroscopy is performed to evaluate the integrity of the rotator cuff including its mobility, thickness, and tissue quality (Video 1). Surrounding tissues also are evaluated to determine the need for additional procedures. The subacromial space and

From Private Practice Sacramento, California (A.M.H., W.J.A.); and Arthrex, Naples, Florida (T.D.), U.S.A.

The authors report the following potential conflicts of interest or sources of funding: A.M.H. reports personal fees from Arthrex, personal fees and other from Clarius Mobile Health, personal fees from LifeNet Health, outside the submitted work; In addition, A.M.H. has a patent, TENSIONABLE CONTRACTS WITH MULTI-LIMB LOCKING MECHANISM THROUGH SINGLE SPLICE AND METHODS OF TISSUE REPAIR, pending to Arthrex, a patent, SUTURE ANCHOR AND METHODS OF KNOTLESS TISSUE FIXATION, pending to Arthrex, a patent, TENSIONABLE CONTRACTS WITH MULTI-LIMB LOCKING MECHANISM THROUGH SINGLE SPLICE, pending to Arthrex, a patent, TENSIONABLE CONTRACTS WITH MULTI-LIMB LOCKING MECHANISM THROUGH SINGLE SPLICE, pending to Arthrex, a patent, SUTURE ANCHOR AND METHODS OF KNOTLESS TISSUE FIXATION, licensed to Arthrex, a patent, SUTURE ANCHOR AND METHODS OF KNOTLESS TISSUE FIXATION, licensed to Arthrex, a patent, MEASURING TOOL USING SUTURE AND SUTURE ANCHOR, licensed to Arthrex, a patent, MEASURING TOOL USING SUTURE AND

SUTURE ANCHOR, licensed to Arthrex, a patent, JOINT KINEMATIC RECONSTRUCTION TECHNIQUES, pending to Arthrex, and a patent, JOINT KINEMATIC RECONSTRUCTION TECHNIQUES, pending to Arthrex. T.D. is an employee of Arthrex. In addition, T.D. has a patent, MEASURING TOOL USING SUTURE AND SUTURE ANCHOR, licensed to Arthrex. These are the products we have on hand to work with at Arthrex. They are all proprietary and unique to complete the canopy repair with a knotless tensionable technique. Full ICMJE author disclosure forms are available for this article online, as [supplementary material](#).

Received April 28, 2020; accepted August 5, 2020.

Address correspondence to Alan M. Hirahara, M.D., F.R.C.S.C., 2801 K St., #330, Sacramento, CA 95816. E-mail: ahirahara@sacortho.net

© 2020 by the Arthroscopy Association of North America. Published by Elsevier. This is an open access article under the CC BY-NC-ND license (<http://creativecommons.org/licenses/by-nc-nd/4.0/>).

2212-6287/20813

<https://doi.org/10.1016/j.eats.2020.08.003>

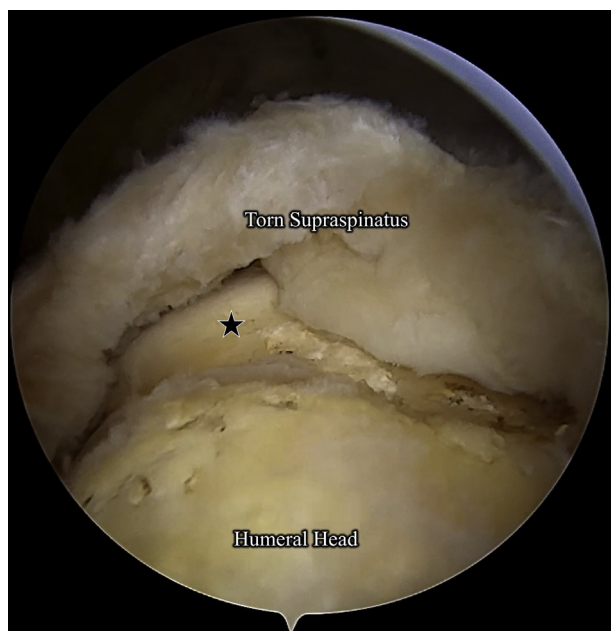


Fig 1. A view through the lateral portal of the right shoulder with a 30° arthroscope with the patient placed in a beach chair position. Seen is a full-thickness tear of the supraspinatus, retracted to the articular margin (star).

pertinent tissues are debrided of any adhesions and released to better visualize the torn rotator cuff and improve its mobility (Fig 1). Using a grasper, the leading edge of the rotator cuff tendon is pulled laterally in an attempt to reduce the tissue to the normal attachment site on the greater tuberosity. In addition, the quality of the rotator cuff tendon tissue is evaluated to further determine repairability and the need for augmentation. If the rotator cuff tear is determined to be amenable to repair but needs additional reinforcement, a rotator cuff repair with canopy graft augmentation is performed.

Rotator Cuff Repair

A SpeedBridge configuration (Arthrex, Naples, FL) is used to repair the full-thickness rotator cuff tear. With the greater tuberosity debrided down to bleeding bone in preparation for the repair, the medial row anchors are placed. A socket is punched along the articular margin anteriorly. A 4.75-mm Knotless BioComposite SwiveLock preloaded with FiberTape (Arthrex) is fixed into the socket. A posteromedial socket is punched, and a second Knotless SwiveLock preloaded with FiberTape is placed in the socket (Fig 2).

The medial row anchors contain a swedged FiberTape suture (Arthrex), a looped shuttle suture, and a repair suture. The suture bundle from the anteromedial anchor is gathered and pulled through the lateral portal. Using a SideLoader Scorpion Suture Passer (Arthrex), a FiberLink (Arthrex) is passed through the rotator cuff. Care should be taken both to be far medial to the rotator cuff tendon edge and to avoid the musculotendinous

junction by 1 cm. The bundle of sutures from the anchor is passed through the looped end of the FiberLink and passed en masse through the rotator cuff. This is repeated for the posteromedial anchor. The distance between the sutures passed through the rotator cuff must be equal to the distance between the anchors.

The swedged FiberTapes are cut. One FiberTape limb from each of the medial row anchors are gathered and attached to a 4.75-mm Knotless BioComposite SwiveLock. A socket is created in the anterolateral greater tuberosity and the anchor is fixed into the socket. The remaining FiberTape limbs are gathered and attached to a second Knotless SwiveLock. A punch is used to create a socket in the posterolateral greater tuberosity and the anchor is fixed into position. The excess FiberTape is cut flush with the lateral anchors. This completes the rotator cuff repair using the SpeedBridge configuration (Fig 3).

If the repaired tendon tissue is thinned and its durability suspect, a Canopy augmentation is indicated to reinforce the repaired tendon (Table 1). Each anchor is accompanied by 2 additional sutures: a repair suture and a looped shuttle suture. These sutures are used to secure an augmentation graft. If an augmentation is not performed, the sutures are simply removed.

Graft Preparation and Fixation

The dimensions of the dermal allograft need to be specific to the construct. To determine the appropriate size of the graft (ArthroFlex 201, 2.0 mm thickness;

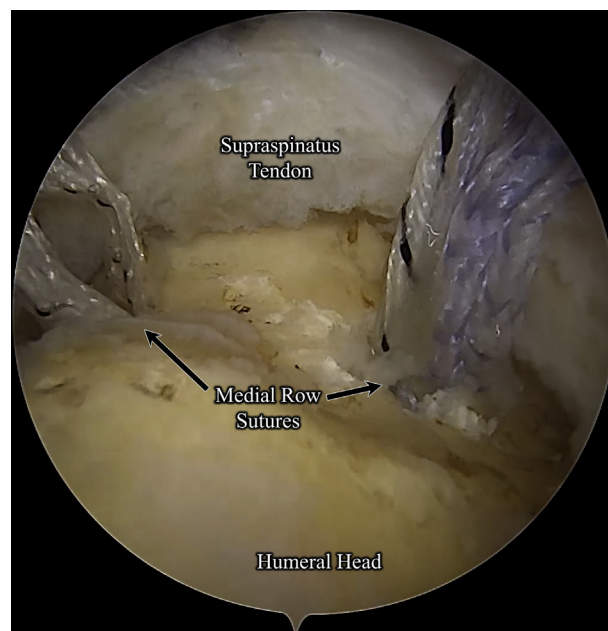


Fig 2. A view through the lateral portal of the right shoulder with a 30° arthroscope with the patient placed in a beach chair position. The medial row anchors have been placed in preparation for the SpeedBridge repair (Arthrex, Naples, FL). The anchors are placed at the articular margin.

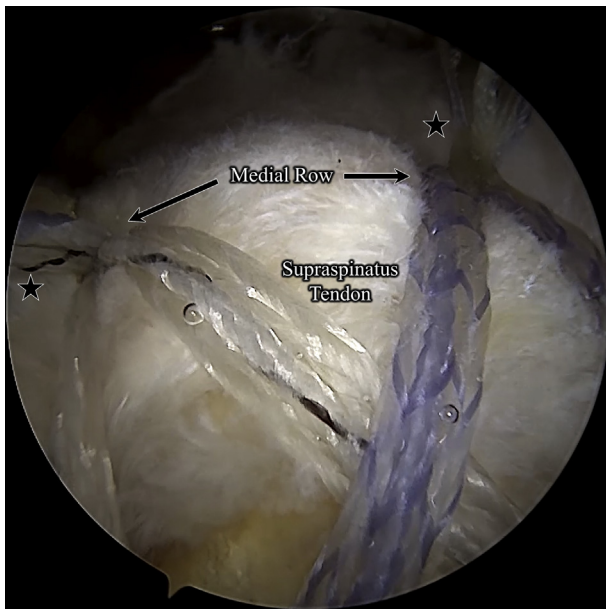


Fig 3. A view through the lateral portal of the right shoulder with a 30° arthroscope with the patient placed in a beach chair position. A completed rotator cuff repair using the SpeedBridge configuration (Arthrex, Naples, FL) can be seen. The medial row knotless sutures can be seen in the background of the image. Each of the anchors have associated repair and looped shuttle suture limbs (stars) that will be used to fix the dermal allograft for augmentation.

LifeNet Health, Virginia Beach, VA) (Fig 4), the distance between each of the 4 anchors is measured intra-articularly using a repair suture and the SCR Guide (Arthrex). The SCR Guide is attached to the repair suture and placed over the anchor of the repair suture. A hemostat is used to mark the zero point on the SCR Guide (Fig 5 A and B). The repair suture is moved to an adjacent anchor, displacing the hemostat from the zero position. The distance from which the hemostat is displaced from the zero position corresponds to the distance between these 2 anchors and the dimension of that side of the graft (Fig 5 C and D). Each repair suture allows for the measurement of 2 adjacent sides of the graft, so using repair sutures from opposing corner anchors will yield the measurements of all 4 sides of the graft. Measurement of each side of the graft is imperative to prevent dog-ears or overtensioning of the graft.

With the graft appropriately measured and trimmed to specifications, a PassPort Divider (Arthrex) is placed in a 12-mm PassPort Cannula (Arthrex) in the




Fig 4. An external view of the 2.0-mm thick dermal allograft (ArthroFlex 201, LifeNet Health, Virginia Beach, VA). The purple markings on the graft indicate where the graft will be trimmed. These markings are based on intra-articular measurements of the distances between the anchors. Measurements are required as the graft needs to be customized to the repair.

anterolateral portal to prevent suture entanglement. This device separates the cannula into 4 compartments. The repair suture and looped end of the shuttle suture for each SwiveLock are gathered and pulled extra-articularly into their respective compartments ensuring the sutures of each anchor remain isolated (Fig 6 A and B). The repair suture is passed through its respective corner of the graft using a SideLoader Scorpion Suture Passer. The repair suture is then loaded through the looped end of the shuttle suture (Fig 7). The remaining limb of the shuttle suture is pulled to thread the repair suture through its corresponding anchor and seat the repair suture in the anchor's locking mechanism. This process is completed for each suture bundle (Fig 8).

The divider is removed from the cannula, and the graft is pushed into the joint using a BackGrasper (Arthrex). With the graft introduced into the joint, the repair sutures are pulled to tension the graft appropriately over the SpeedBridge repair. The excess repair sutures are cut. A biologic may be now placed in-situ both under the tendon repair at the bone interface and under the canopy between the graft and tendon. The canopy will help keep the biologic in place. This completes the Canopy augmentation of the rotator cuff repair with a decellularized dermal allograft (Fig 9).

Rehabilitation

The rehabilitation for this technique would follow a standard protocol for a rotator cuff repair. Our rotator cuff repair protocol consists of 5 phases under the guidance and direction of a physical therapist. Phase I

Table 1. Indications and Contraindications

Indications	Contraindications
Repairable full-thickness rotator cuff tear	Inelastic rotator cuff tissue
Thinned tissue	Excessive tension on repaired rotator cuff
Mobilizable tissue	Severe osteoarthritis

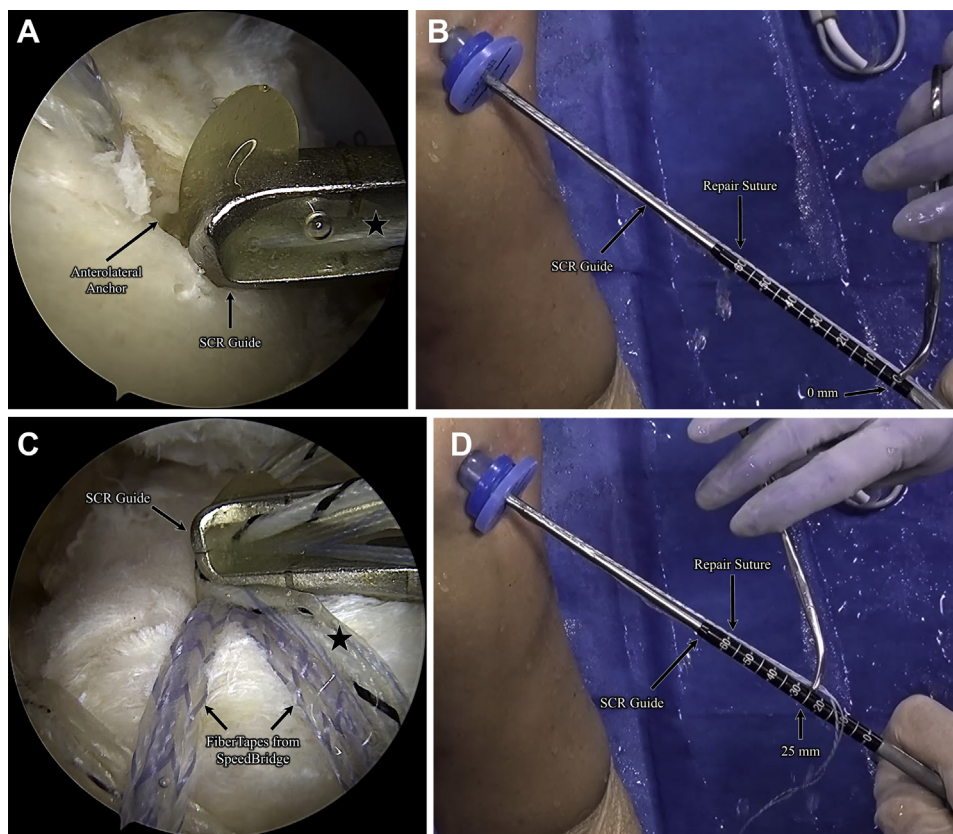


Fig 5. (A) An arthroscopic view through the lateral portal of the right shoulder, using a 30° arthroscope of the anterolateral anchor and its associated repair suture with the patient placed in a beach chair position. The SCR Guide (Arthrex, Naples, FL) is attached to the repair suture and will be used to determine the distances between the adjacent anchors. (B) An external view of the SCR Guide (Arthrex) used to make a measurement of the intra-articular distance between anchors in the SpeedBridge construct (Arthrex). The SCR Guide is attached to the repair suture. A hemostat is used to mark where the zero position is on the repair suture. (C) An arthroscopic view through the lateral portal of the right shoulder using a 30° arthroscope of the SCR Guide (Arthrex) placed over the location of the anteromedial anchor. The SCR Guide is attached to the repair suture (black star) from the SpeedBridge construct (Arthrex) and used to measure the distance from its original position at the anterolateral anchor, as seen in (A). The repair suture is distinct from the FiberTape sutures (Arthrex.) used in the SpeedBridge rotator cuff repair. (D) An external view of the SCR Guide (Arthrex) used to make a measurement of the intra-articular distance between anchors in the SpeedBridge construct (Arthrex). The repair suture has been moved to the site of the anteromedial anchor, as seen in (C). This has displaced the hemostat 25 mm from its original position at the zero mark on the SCR Guide. This indicates that the distance between the anterolateral and anteromedial anchors is 25 mm, which will be the anterior dimension of the graft.

(weeks 1-3) is focused on regaining pain-free passive range of motion (ROM) while diminishing pain and decreasing muscle tightness and spasm. Phase II (weeks 3-6) allows patients to begin active-assisted ROM and removal of the sling (without bolster) after week 4. By the end of phase II, patients should have achieved 70% to 80% of ROM in all planes. Phase III is divided into “early” and “late” phases, with the goals of Early Phase III (weeks 7-10) aimed at improving coordination in controlled movements and return of full ROM. Active ROM exercises against gravity and light tubing/scapular stabilization exercises are permitted. Patients should have achieved full active and passive ROM by the end of Late Phase III (weeks 11-16). In this Late phase, patients continue to progress with their tubing and

scapular stabilization exercises and focus on establishing a foundation for the gradual restoration of shoulder strength and power. Phase IV (months 4-5) is strength-focused while maintaining full, pain-free ROM. Fast-twitch controlled movements are initiated and patients are gradually returned to functional activities. In Phase V (months 6+), patients continue to gradually return to functional, strenuous work, and recreational sport activities.

Discussion

Tissue mobility, quality, and tension are important considerations when determining the ideal method of surgical repair of full-thickness rotator cuff tears. If the rotator cuff tendon is unable to mobilize to the footprint

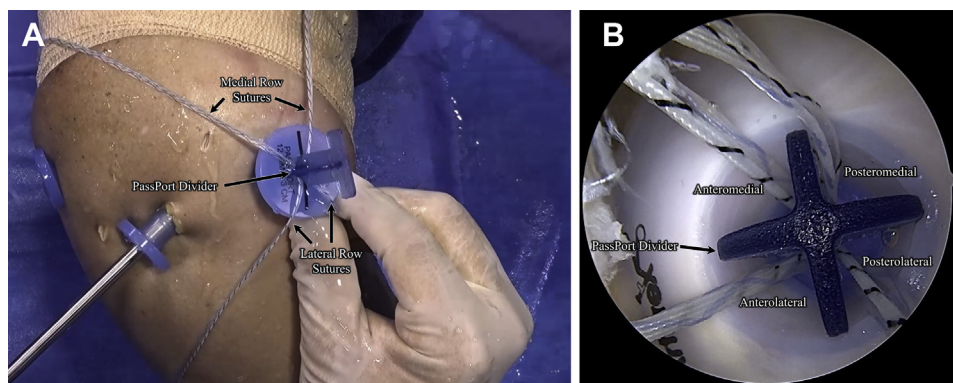


Fig 6. (A) An external view of the right shoulder with the patient placed in a beach chair position. A PassPort Divider (Arthrex, Naples, FL) is placed in the anterolateral 12-mm PassPort Cannula (Arthrex). Each anchor is accompanied by 2 sutures: a repair suture and a looped passing suture. The sutures from the medial row anchors are pulled through superior compartments of the divider and the sutures from the lateral row anchors are in the inferior compartments. (B) A view through the lateral portal of the right shoulder using a 30° arthroscope of the PassPort Divider (Arthrex) placed in the anterolateral cannula. The repair and looped shuttle sutures from the various anchors can be seen in their individualized compartments.

or if there is excessive tension on the mobilizable tendon, procedures like the SCR or SCR combined with cuff repair¹⁻⁵ should be favored over primary repair. For the repairable tear, poor tissue quality necessitates graft augmentation to provide additional thickness.

A repair alone for a mobile, yet thinned rotator cuff may lead to a poor outcome. The thinned tissue may not be able to hold the high-tensile strength sutures, or, even if the tendon heals, it may not withstand the forces required for day-to-day activities and ultimately

result in a retear. This will result in the further loss of tendon tissue and make future revisions more difficult or impossible. In these settings, augmentation with a patch may improve the prognosis by thickening the tissue (Table 2). Graft augmentations can be completed in a variety of ways and can be either incorporated into the repair as part of the construct like the BioBridge (Arthrex) or, as detailed in this manuscript, laid on top of a repair like a canopy. The goal of this Canopy method is not meant to strengthen the repair but rather to add tissue to the rotator cuff tendon to make it more robust and resistant to retear.⁶

The ArthroFlex decellularized dermal allograft (LifeNet Health) is remarkably strong and has existing vascular

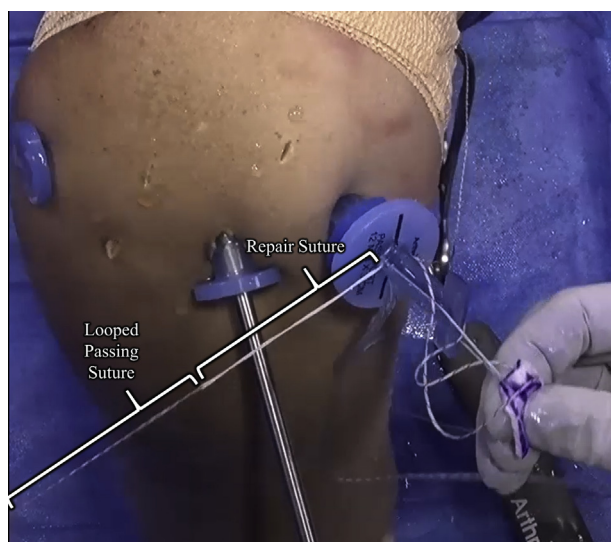


Fig 7. An external view of the sutures used to fix the dermal allograft with the patient placed in a beach chair position. Three suture limbs from 2 sutures are used: one repair suture (which is fixed to the anchor) and 2 limbs from the looped shuttle suture. The repair suture is passed through the corresponding graft corner and then is loaded through the looped end of the shuttle suture. The looped shuttle suture can be pulled to pass the repair suture back through the knotless anchor. This process is repeated for each corner.

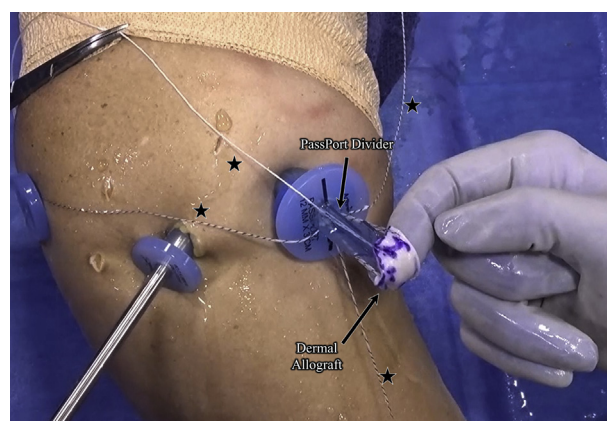


Fig 8. An external view of the graft with the patient placed in a beach chair position, with all repair sutures passed through their designated corners of the graft and their corresponding anchors. The PassPort Divider (Arthrex, Naples, FL) will be removed before when the graft is pushed into the joint. After the graft is introduced into the joint with a BackGrasper (Arthrex), the repair sutures (black stars) will be tightened to fix the graft in place.

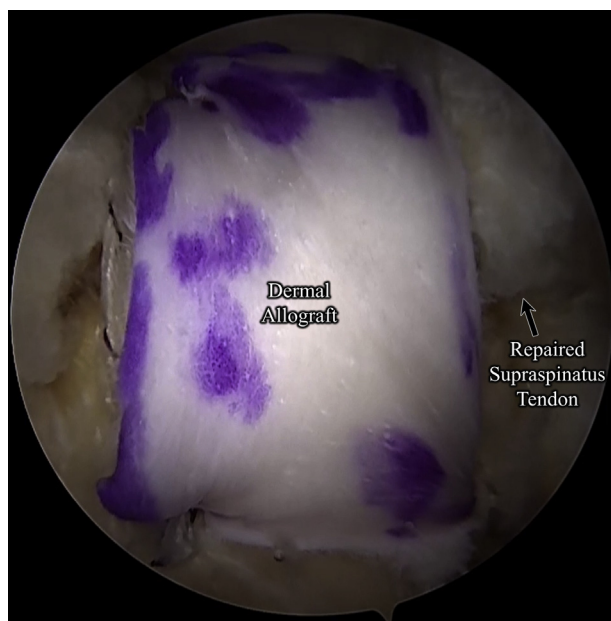


Fig 9. A view through the lateral portal of the right shoulder with a 30° arthroscope with the patient placed in a beach chair position. The dermal allograft canopy augmentation is seen sitting over the supraspinatus tendon repair. This is the final construct.

channels.^{2,3} The graft has been shown to incorporate, revascularize, and recellularize over time when used in SCR.^{2,3,7} At time point zero of implantation, the graft just sits on the repair. Once it adheres and integrates, the tendon will have a greater cross-sectional area, which will give it greater strength and ability to withstand tearing.⁶ In addition to being thicker, the inherent,

Table 2. Advantages and Limitations

Advantages	Limitations
The technique uses a standard rotator cuff repair with a double-row construct and then allows the surgeon to simply augment the repair as necessary without additional anchors or knot tying.	Canopy augmentation is not ideal for rotator cuff that cannot be mobilized or has too much tension upon repair.
A tissue spreader and holder is not necessary.	ArthroFLEX graft may not be accessible worldwide.
The ArthroFLEX graft is very strong, resistant to suture pull-through, and has minimal DNA, which decreases the chance of an inflammatory reaction.	
The ArthroFLEX graft is capable of incorporation, revascularization, and recellularization by the host. ^{2,3}	
The technique allows placement of a biologic under the graft, which will hold it in place.	

Table 3. Pearls and Pitfalls

Pearls	Pitfalls
The PassPort Divider prevents suture crossing and entanglement.	Avoid suture crossing and entanglement.
Knotless anchor technology allows for easy graft fixation without extra hardware.	Avoid musculotendinous junction during rotator cuff repair.
Knotless anchor technology negates need for knot stacks that would cause damage to tissue.	
If augmentation is not performed, the passing suture is pulled out, and the repair suture is cut. They also may be used alternatively as dog-ear repair sutures, additional tightening sutures, or horizontal mattress buttressing.	

native strength of the dermal allograft, which has been shown to have a high ultimate pull to failure,⁸ will buttress the tendon even further, considerably enhancing the repair once integrated.

Rotator cuff augmentation has been avoided due to surgical complexity⁹⁻¹³ and poor graft selection.¹⁴ The method of graft fixation and use of a cannula divider to assist in suture management in this Canopy technique simplifies the augmentation procedure (Table 3). In addition, the knotless anchor technology avoids knot tying and knot stacks, which have shown to cause damage to peripheral tissues by attrition.¹⁵⁻¹⁷ This technique offers surgeons addressing mobile but thinned rotator cuff tears an excellent option for repair with dermal allograft augmentation.

References

- Hirahara AM, Adams CR. Arthroscopic superior capsular reconstruction for treatment of massive irreparable rotator cuff tears. *Arthrosc Tech* 2015;4:e637-e641.
- Hirahara AM, Andersen WJ, Panero AJ. Superior capsular reconstruction: Clinical outcomes after minimum 2-year follow-up. *Am J Orthop* 2017;46:266-278.
- Hirahara AM, Andersen WJ, Panero AJ. Ultrasound assessment of the superior capsular reconstruction with dermal allograft: An evaluation of graft thickness and vascularity. *Arthroscopy* 2019;35:3194-3202.
- Mihata T, Lee TQ, Watanabe C, et al. Clinical results of arthroscopic superior capsule reconstruction for irreparable rotator cuff tears. *Arthroscopy* 2013;29:459-470.
- Pennington WT, Chen SW, Bartz BA, Pennington JM. Superior capsular reconstruction with arthroscopic rotator cuff repair in a "functional biologic augmentation" technique to treat massive atrophic rotator cuff tears. *Arthrosc Tech* 2019;8:e465-e472.
- Mazzocca AD, Rincon LM, O'Connor RW, et al. Intra-articular partial-thickness rotator cuff tears: Analysis of

- injured and repaired strain behavior. *Am J Sports Med* 2008;36:110-116.
7. Plachel F, Klatte-Schulz F, Minkus M, Bohm E, Moroder P, Scheibel M. Biological allograft healing after superior capsule reconstruction. *J Shoulder Elbow Surg* 2018;27:e387-e392.
 8. Barber FA, Herbert MA, Boothby MH. Ultimate tensile failure loads of a human dermal allograft rotator cuff augmentation. *Arthroscopy* 2008;24:20-24.
 9. Barber FA, Burns JP, Deutsch A, Labbe MR, Litchfield RB. A prospective, randomized evaluation of acellular human dermal matrix augmentation for arthroscopic rotator cuff repair. *Arthroscopy* 2012;28:8-15.
 10. Gouk CJC, Shulman RM, Buchan C, Thomas MJE, Taylor FJ. Failure of dermal allograft repair of massive rotator cuff tears in magnetic resonance imaging and clinical assessment. *Clin Orthop Surg* 2019;11:200-207.
 11. Hohn EA, Gillette BP, Burns JP. Outcomes of arthroscopic revision rotator cuff repair with acellular human dermal matrix allograft augmentation. *J Shoulder Elbow Surg* 2018;27:816-823.
 12. Laskovski J, Abrams J, Bogdanovska A, Taliwal N, Taylor M, Fisher M. Arthroscopic rotator cuff repair with allograft augmentation: Making it simple. *Arthrosc Tech* 2019;8:e597-e603.
 13. Petri M, Warth RJ, Horan MP, Greenspoon JA, Millett PJ. Outcomes after open revision repair of massive rotator cuff tears with biologic patch augmentation. *Arthroscopy* 2016;32:1752-1760.
 14. Walton JR, Bowman NK, Khatib Y, Linklater J, Murrell GA. Restore orthobiologic implant: Not recommended for augmentation of rotator cuff repairs. *J Bone Joint Surg Am* 2007;89:786-791.
 15. Dines JS, ElAttrache NS. Horizontal mattress with a knotless anchor to better recreate the normal superior labrum anatomy. *Arthroscopy* 2008;24:1422-1425.
 16. Hanypsiak BT, DeLong JM, Simmons L, Lowe W, Burkhart S. Knot strength varies widely among expert arthroscopists. *Am J Sports Med* 2014;42:1978-1984.
 17. Kim SH, Crater RB, Hargens AR. Movement-induced knot migration after anterior stabilization in the shoulder. *Arthroscopy* 2013;29:485-490.